

COMPARISON OF OUTCOME OF LOCKING PLATE FIXATION AND CLOSED INTRA MEDULLARY INTER LOCKING NAIL IN THE MANAGEMENT OF EXTRA ARTICULAR DISTAL TIBIAL FRACTURES IN ANDHRA PRADESH POPULATION

Y. Panduranga Rao¹, K. N. Sandeep¹, Pagidimarri Manasa², Bhanu Pratap B¹

Received : 27/10/2025
Received in revised form : 11/12/2025
Accepted : 30/12/2025

Keywords:
Intensifier, Weight bearing, Locking plate, ILN (Inter locking Nail).

Corresponding Author:
Dr. K. N. Sandeep,
Email: kn.sandy@gmail.com

DOI: 10.47009/jamp.2026.8.1.13

Source of Support: Nil,
Conflict of Interest: None declared

Int J Acad Med Pharm
2026; 8 (1); 64-68



¹Associate Professor, Department of Orthopaedics, Santhiram Medical College, Nandyal, Andhra Pradesh, India

²Assistant professor, Department of Orthopaedics, Santhiram Medical College and General Hospital Nandyal, Andhra Pradesh, India

ABSTRACT

Background: Treating the distal tibial fracture is a great challenge to orthopedic surgeons because of its unique anatomical characteristics of subcutaneous location with precarious blood and proximity to the ankle joint leading to postoperative complication. Hence safer, ideal techniques are needed to treat such complicated fractures. **Materials and Methods:** Out of 50 patients, 25 were operated on with an interlocking nail and 25 with locking plate fixation. Patients were regularly followed up to 1 year post-operatively, assessed clinically and radiologically to rule out any complications, and treated properly. **Result:** Duration of surgery techniques 18 (72%) of ILN and 10 (40%) in plating had a duration of 40-60 minutes; 7 (28%) in ILN and 10 (40%) in plating had a duration of 61-80 minutes; and 5 (20%) plating durations were > 80 minutes. More duration of body weight bearing after surgery was observed >14 weeks in the plating technique. 3 (12%) post-surgical complications were more or less the same in both groups. **Conclusion:** It is proved that, the closed intramedullary interlocking nail technique was more preferred than the plating technique because of early weight bearing, early union of fractures, and decreased implant-related problems.

INTRODUCTION

Due to the increase in urbanization and thick population. There is speed and fast-moving vehicles, severe fractures, and fatalities.^[1] The aim of treatment by an orthopedic surgeon is to treat fractures for early union in the most comfortable anatomical position, which allows maximal and full restoration of extremities.^[2]

The tibia is one of the most commonly fractured long bones as compared to other bones of the body, on the contrary. The tibia is the most notorious bone for delayed union because of less blood supply.^[3] This is because the tibia provides attachment for tendons instead of fleshy muscles. Distal tibial fractures are primarily located within the distal tibia. On the basis of the fracture location of the bone, distal tibial fractures have the second-highest incidence of all tibial fractures after the middle part of the tibia.

Management of distal tibial fractures is more challenging to orthopedic surgeons because of its anatomical characteristic of subcutaneous location with precarious blood supply and proximity to the

ankle joint, leading to the potential for postoperative complications and poor outcomes.^[4] Hence, an attempt is made to compare the intramedullary interlocking nail and locking plate fixation technique in the management of extra-articular distal tibial fractures.

MATERIALS AND METHODS

50 (fifty) patients admitted to the orthopedic department of Santhiram Medical College Hospital, Nandyal, Andhra Pradesh-518501, were studied.

Inclusion Criteria

Patients aged between 18 to 50 years. Presence of a distal fragment at least 3 cm in length without articular incongruity. Duration of injury less than 2 weeks and no involvement of neurovascular status. The patients who gave their consent for the study in writing were selected.

Exclusion Criteria

Patients with open fractures, intra-articular extension, pathological fractures, or poor medical health were excluded from the study.

Method: 50 patients with distal tibia extra-articular fractures. AO type 43A. Out of 50 patients, 25 were operated on with interlocking nailing and 25 with locking plates. Radiographic examination was done. Antero-posterior (AP view) and lateral view of the defected limb: patients were operated on under spinal anesthesia. An antibiotic of the third-generation cephalosporin was given intravenously 15 minutes before surgery. A pneumatic tourniquet/ES March rubber tourniquet was used in all patients. The affected limb was thoroughly scrubbed from mid-thigh to foot with Betadine scrub and Savlon. The limb was painted with Betadine solution from thigh to foot. The rest of the body and the other limb were properly draped with sterile drapes. Cases in which the fibula was fixed in addition to nailing or plating of the tibia were done either with a one-third semitubular plate, a reconstruction plate, or a Rush nail. In cases fixed with plating, the incision was taken just posterior to where soft tissues were dissected, and the reduction of the fracture fragments was achieved after cleaning the fracture site. The fracture was fixed with a six- or seven-hole plate with screws. In cases of rash nail fixation, it was passed percutaneously over a stab incision at the tip of the lateral malleolus after reduction of the fracture manually. The passage and location of the nail were checked under an image intensifier.

Surgical technique for intramedullary nailing: A vertical patellar tendon-splitting incision over skin extending from the center of the inferior pole of the patella to the tibial tuberosity was made about 3 cms long. The patellar tendon was split vertically in its middle and retracted to reach the proximal part of the tibial tuberosity. The next step was to determine the point of insertion. Essential for the success of the procedure is the correct choice of insertion point. After selecting the point of insertion, a carved bone awl is used to breach the proximal tibial cortex. In the metaphysical cancellous bone, an entry portal was created, making sure it was in line with the center of the medullary canal. After widening the medullary canal with a curved awl, a guide of size 3 mm diameter x 950 mm length was passed into the medullary canal of the proximal fragment.

Accurate closed reduction of the fracture was verified under the image intensifier before insertion of the guide wire in the distal tibial metaphysis. After reduction, the tip of the guide wire was passed till it entered the subchondral bone of the distal tibia. The exact length of the nail was measured from the length of the guide wire remaining inside the medullary canal from the entry point.

The size of the nail was assessed as one millimeter less than the diameter of the last reamer and passed into the medullary canal over the guide wire. Screw positions were confirmed under a C-arm image intensifier. After this zig was removed, stability was checked by performing flexion and extension at the knee and ankle joints. All incisions were closed in layers, and a sterile dressing was applied over the wound.

Surgical technique for locking plate Fixation: The concept of this approach was to preserve the soft tissues and blood supply. A straight or slightly curved skin incision was performed on the medial aspect of the distal tibia. The length of the incision varied from 3-5 cms depending on the type of planned plate.

The incision ended distally at the tip of the medial malleolus. The incision was carried out straight across the subcutaneous fat, preserving the great saphenous vein and saphenous nerve; they were held anteriorly with a blunt retractor. The dissection advanced down onto the periosteum, which was completely preserved. In this anatomical space, the tunneling towards the diaphysis was achieved with the blunt tip of the plate. For the insertion of the proximal screws in the diaphysis, separate stab incisions were made. The plate was inserted after proximal tunneling with the plate itself. It is important to note that the plate and the proximal screw should be centered on the tibia, particularly if locking head screws are planned.

Temporary fixation was performed with the wires through the screw holes to approximate the final plate position before the screw insertion. For spiral and short oblique fracture patterns that were anatomically reduced, lag screws were placed to enhance the stability. The screws were placed independent of the plate. A conventional screw was inserted in one of the most distal plate holes to approximate the plate close to the bone after achieving an accurate position of the plate. All the incisions were closed in the layers. Sterile dressing was applied over the knee plaster; a slab was applied below the knee in all patients.

Postoperatively, radiographs were taken. Passive knee and ankle range of motion was started in the 1st postoperative week, depending upon the type of fracture and stability of fixation. Active movements started in the 2nd week, once pain had subsided. The weight-bearing was planned as per the types of fracture fixation and general condition of the patient. Initially partial weight bearing was advised between 4 to 8 weeks, and then full weight bearing was advised when there was formation of callus and union of fracture process was observed radiologically.

Clinical follow-up examination was at 4 weeks, 6 weeks, 10 weeks, 3 months, 6 months, and 1 year. Every patient was assessed clinically and radiologically to rule out tenderness at the fracture site, abnormal mobility, and infection. Pain on movement of knee and ankle joint.

The duration of the study was from January 2023 to July 2024.

Statistical Analysis: The results were compared with percentages. The duration of union of fracture was compared with a Z-test. The statistical analysis was carried out using SPSS software. The ratio of male and female was 3:1.

RESULTS

[Table 1] AO classification of fractures –

- 42A-1: 12 (48%) in ILN group, 12 (48%) in plating group.
- 43A-2: 8 (32%) in ILN group, 8 (32%) in plating group.
- 43A-3: 5 (20%) in ILN group, 5 (20%) in plating group.

[Table 2] Comparison of duration of surgery in both techniques Duration (in minutes)

- 40-60 minutes: 18 (72%) in ILN, 10 (40%) in plating group, total 28 (56%)
- 61-80 minutes: 7 (28%) in ILN, 10 (40%) in plating group, total 17 (34%)
- > 80 minutes: only in plating 5 (20%)

[Table 3] Comparison of duration of body weight bearing after surgery in both techniques

Duration (in minutes):-

- 8-10 weeks: 18 (72%) in ILN group, 3 (12%) in plating group, total 21 (42%)
- 11-12 weeks: 7 (28%) in ILN group, 7 (28%) in plating group, total 14 (28%)

- 13-14 weeks: only in plating 12 (48%), total 12 (24%).
- 14 weeks: only in plating 3 (12%), total is 3 (6%).

[Table 4] Comparison of duration of fracture union (radiological study)

- 16.38 (± 1.42) in ILN technique, 20.72 (± 1.68) in plating, t test was 9.8 and $p < 0.001$ (p value is highly significant)

[Table 5] Comparison of post surgical complications

- Pain in anterior knee: 5 (20%) in ILN group only
- Superficial infection: 1 (4%) in plating group only
- Deep infection: 3 (12%) only in plating technique
- Valgus > (angulation): 5 (20%) in ILN group, 3 (12%) in plating group
- Stiffness of knee: 3 (12%) only in ILN group
- Stiffness of ankle: 1 (4%) in ILN group, 5 (20%) in plating group
- Non-union: 1 (4%) only in ILN group
- Implant irritation: 5 (20%) in plating group only
- Implant failure: 1 (4%) only in ILN group.

Table 1: AO classification of fractures. No of Total Patients: 50

Type of AO	Groups			
	ILN (25)	%	Plating (25)	%
42A-1	12	48	12	48
43A-2	8	32	8	32
43A-3	5	20	5	20

Table 2: Comparison of duration of surgery in both techniques. No of Total Patients: 50

Duration (in minutes)	ILN (25)		Plating (25)		Total	
	No	%	No	%	No	%
40-60 minutes	18	72	10	40	28	56.6
61-80 minutes	7	28	10	40	17	34
> 80 minutes	0	0	5	20	5	10

Table 3: Comparison of duration of body weight bearing after surgery in both techniques. No of Total Patients: 50

Duration (in minutes)	ILN (25)		Plating (25)		Total (50)	
	No	%	No	%	No	%
8-10 weeks	18	72	3	12	21	42
11-12 weeks	7	28	7	28	14	28
13-14 weeks	0	--	12	48	12	24
> 14 weeks	0	--	3	12	3	6

Table 4: Comparison of duration of fracture union (radiological study). No of Total Patients: 50

ILN (25)	Plating (25)	t test	p value
16.38 (± 1.42)	20.72 (± 1.68)	9.8	$P < 0.001$

P value is highly significant

Table 5: Comparison of post-surgical complication in both groups

Details	ILN	%	Plating	%
Pain in anterior knee	5	20	0	--
Superficial infection	0	--	1	4
Deep infection	0	--	3	12
Valgus > (angulations)	5	20	3	12
Stiffness of knee	3	12	0	--
Stiffness of ankle	1	4	5	20
Non-union	1	4	--	0
Implant irritation	0	--	5	20
Implant failure	1	4	--	--

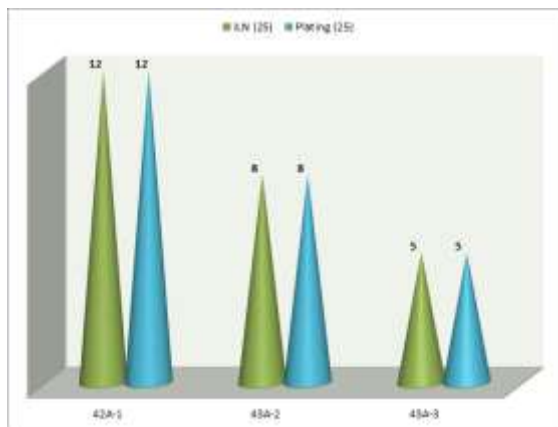


Figure 1: AO classification of fractures

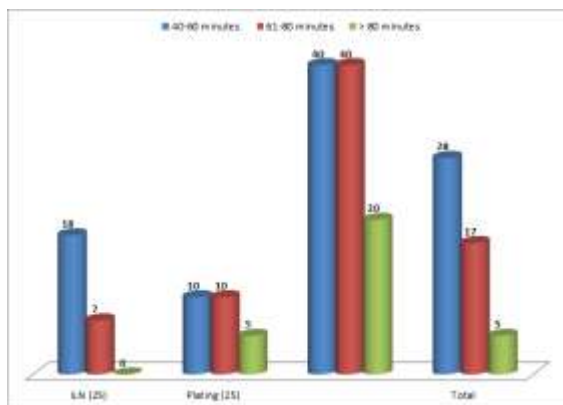


Figure 2: Comparison of duration of surgery in both techniques

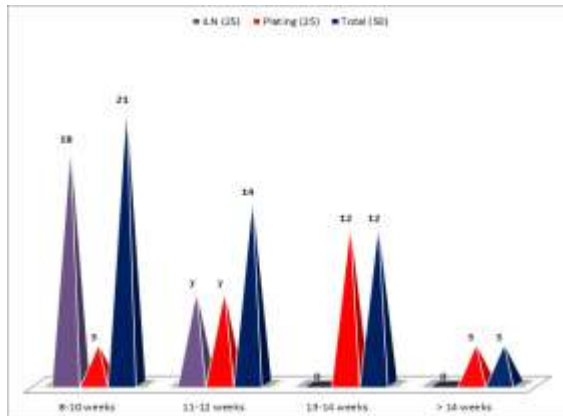


Figure 3: Comparison of duration of body weight bearing after surgery in both techniques

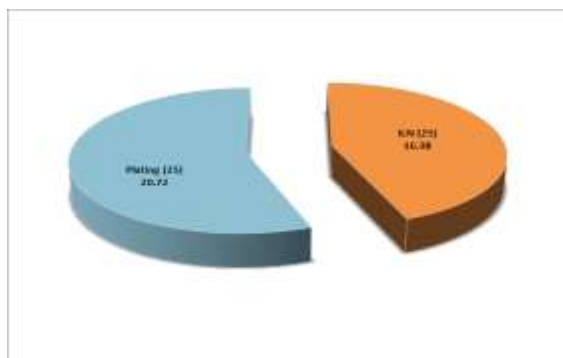


Figure 4: Comparison of duration of fracture union (radiological study)

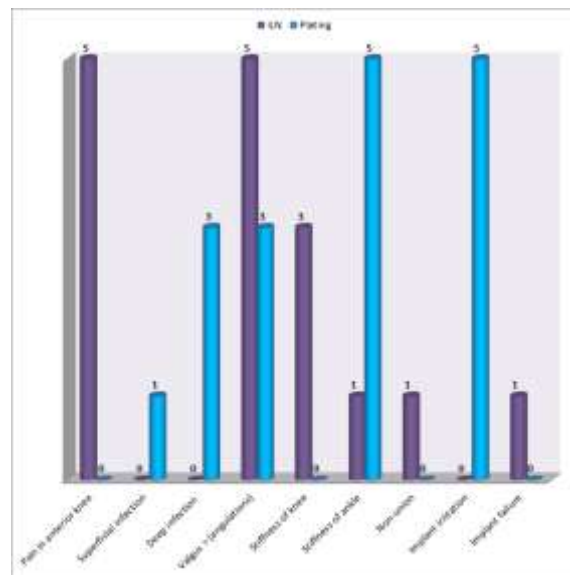


Figure 5: Comparison of post-surgical complication in both groups

DISCUSSION

In the present comparison of the outcome of locking plate fixation and closed intramedullary interlocking nail in the management of extra-articular distal tibial fracture. Duration of surgery in the ILN technique 18 (72%) and 10 (40%) were plating for 40-60 minutes, 7 (28%) were ILN, 10 (40%) were plating for 61-80 minutes, and 5 (20%) plating surgery durations were > 80 minutes [Table 2]. In the comparison of duration of body weight after surgery, 22 (73.3%) in ILN and 4 (13.3%) in plating were 8-10 weeks; 8 (26.6%) in ILN and 8 (26.6%) in plating were 11-12 weeks; 14 (23.3%) in plating were 13-14 weeks; and 3 (12%) in plating were > 14 weeks. Hence, plating technique patients took longer than ILN technique patients [Table 3]. The duration of fracture union was earlier in ILN technique than in plating technique patients. 16.38 (± 1.42) in ILN and 20.72 (± 1.68) in plating, the t-test was 9.8 and $p < 0.001$; the p-value was highly significant [Table 4]. Post-surgical complications were more or less the same in both techniques [Table 5]. These findings are more or less in agreement with previous studies.^[5-7]

Distal tibia fractures generally require operative management and can be managed with closed reduction and intramedullary nailing or open reduction and internal fixation with plating or closed reduction and percutaneous plating or external fixators.^[8]

Locked intramedullary nailing has the advantage of shorter operating time. Intramedullary nailing enables closed stabilization while preserving vascularity of the fracture site and integrity of the soft tissue envelope. Open reduction and internal plate fixation result in extensive soft tissue dissection and may be associated with wound complication and infection.

Recently, percutaneous plating has been a popular method used for unstable distal tibial fractures. This

alternate method also minimizes the risk of infection and soft tissue dissection. Locked plate designs act as fixed-angle devices whose stability is provided by the axial and regular stability at the screw-plate interface instead of relying on the frictional force between the plate and bone, which is thought to preserve the periosteal blood supply around the fracture site.^[9]

Intermedullary nails are commonly used for distal tibia fractures where the fracture is away from the plafond, allowing two or more distal locking than plating, which is technically more challenging to achieve and maintain reduction because of the anatomic characteristics of the distal tibia.^[10] Hence, management of distal tibia fractures with an intramedullary interlocking tibia nail gives better results as compared to fractures managed with a distal tibia locking plate.

CONCLUSION

Both intramedullary nailing and locking plating can be used safely to treat OTA type-43A distal metaphyseal fractures of the tibia. Closed nailing has the advantages of shortened operating time, early weight bearing, decreased wound problems, early union of fractures, decreased implant-related problems, and cost-effectiveness. Hence,

intramedullary interlocking nailing in the treatment of distal tibia fractures was preferred.

Limitation of study: Owing to remote location of research centre, small number of patients, lack of latest techniques we have limited finding and results.

REFERENCES

1. Schatzker J, Tile M: Rationale of operative fracture care, 3rd edition. Springer Verlag Berlin Heidelberg 2005, 475-76.
2. Rockwood and Green fractures I Adults, seventh edition, 2010, vol.-I, 103-6.
3. Borrelli J, Jr., Prikett W: Extra-osseous blood supply of the tibia and the effects of different plating techniques J. Orth. Trauma. 2002, 16 (1); 601-695.
4. Habernek H, Kwasny O: Complications of interlocking nailing for lower leg fractures J. of Trauma 1992, 33; 863-869.
5. Court Broun CM, Birnie J: Epidemiology of tibia fractures J. Bone Joint Surgery 1995, 77B; 417-421.
6. Jorgensen TE: The influence of tibial fracture or pseudoarthrosis Acta Orthop. Scand. 1974, 45; 119-29.
7. Guo JJ, Tang N: A prospective, randomized trial comparing closed intermedullary nailing with percutaneous plating in distal tibia fractures J. Bone Joint Surg. R. 2010, 92; 984-8.
8. Powar ED, Agarwal SR, Patil A: A comparative study of intramedullary nailing with percutaneous plating in the management of extra-articular distal tibial fracture J. Evol. Med. Dent. Science 2014, 3; 6812-26.
9. Mushtaq A, Shahid R: Distal tibial fractures fixation with locking compression plate (LCP) using minimally invasive percutaneous osteosynthesis (MIPO) technique. Eur. J. Trauma Emerg. Surg. 2009, 35; 159-64.
10. Ram GG, Kumar D: Surgery dilemma in treating distal third leg fractures. Int. Surg. J. 2014, 1; 13-6.